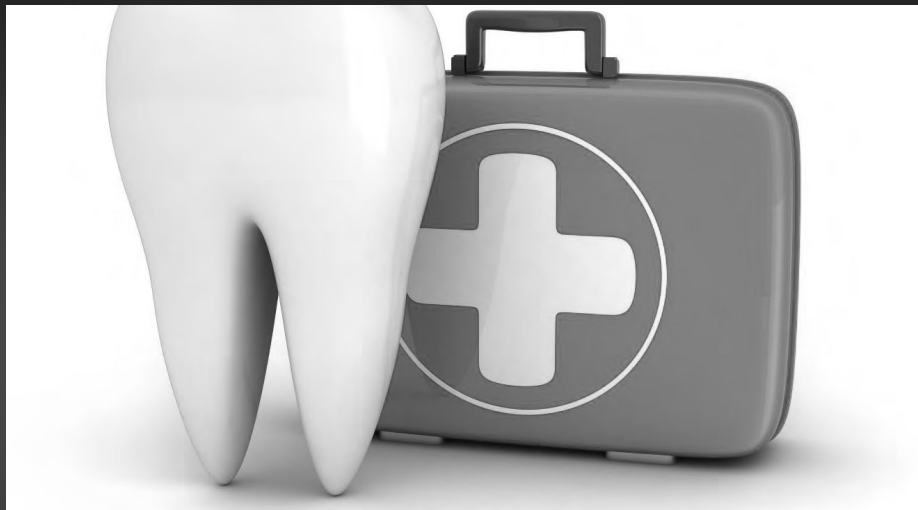


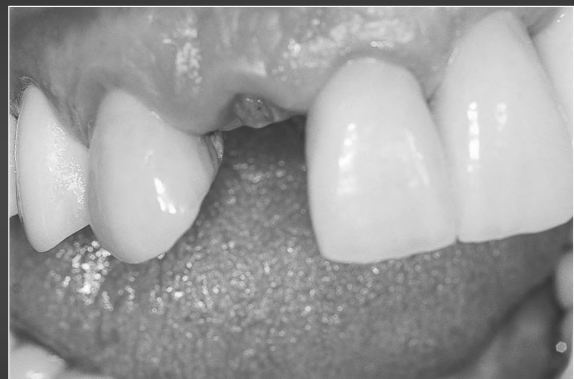
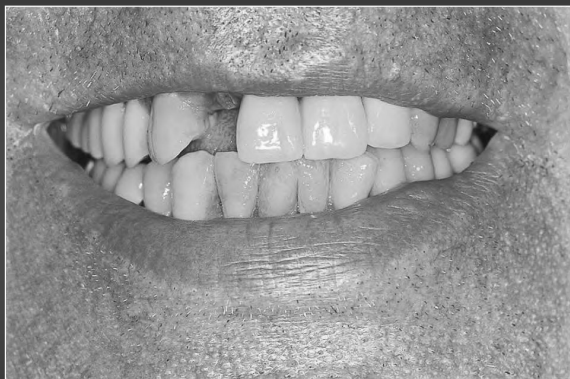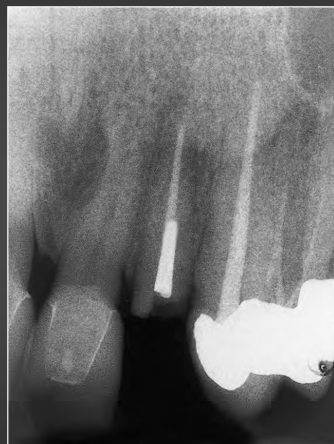
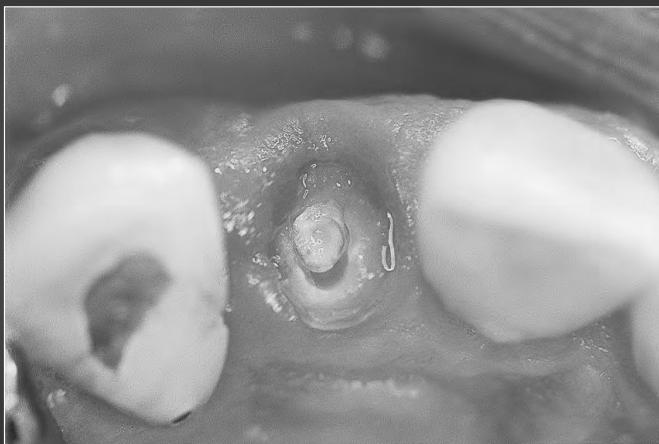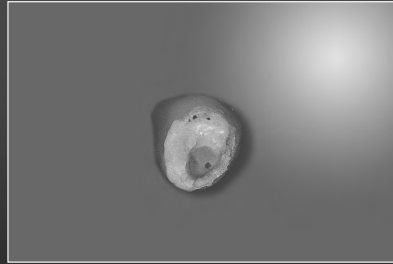
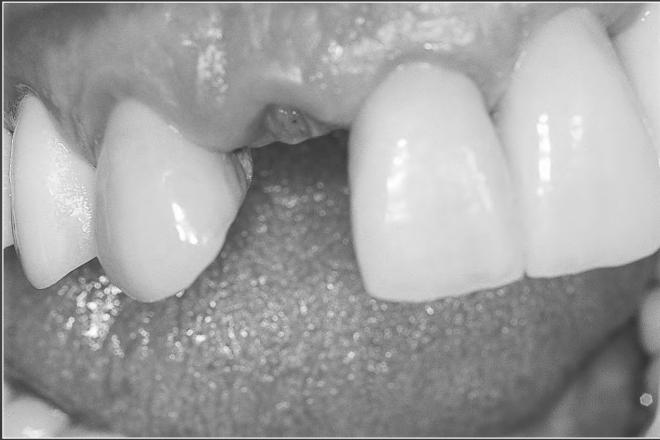Dentale Trickkiste


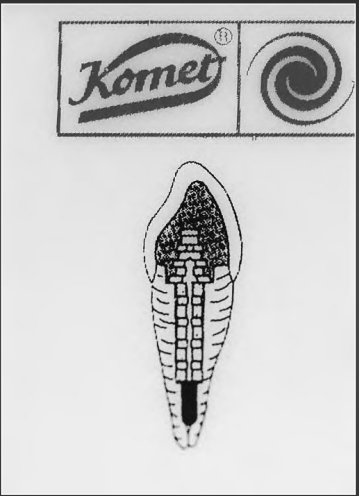
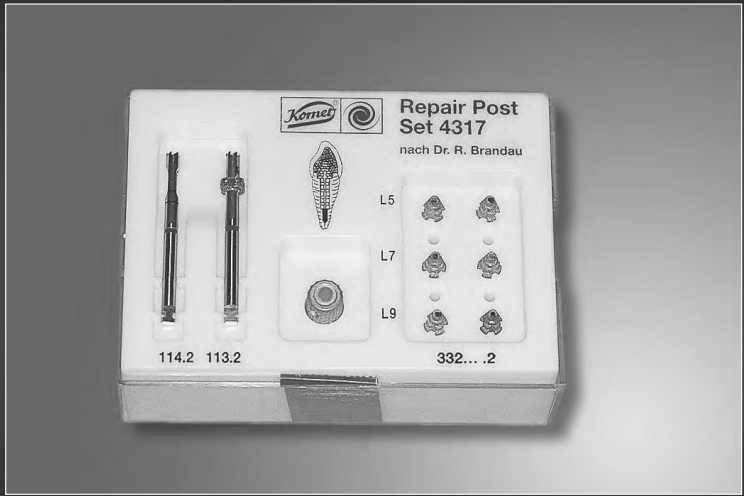

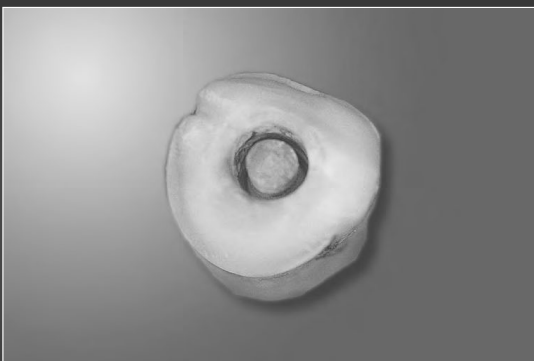
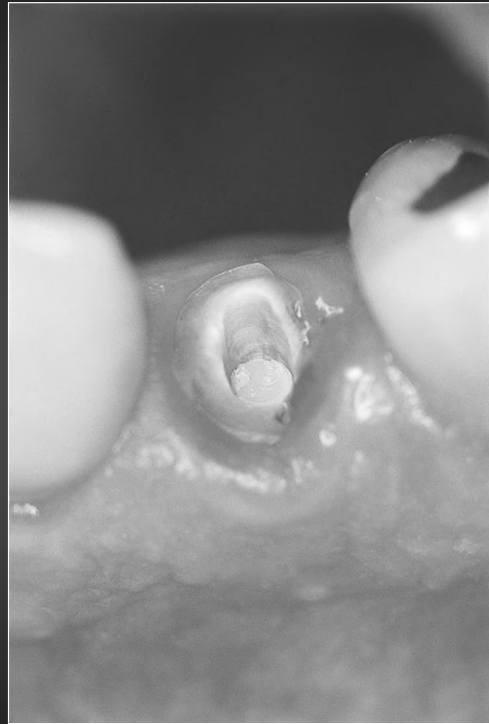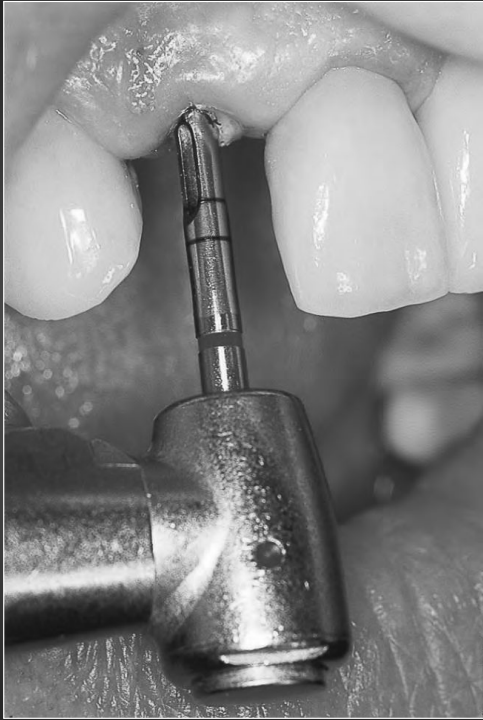Manchmal hängt man
schon richtig in den Seilen.....

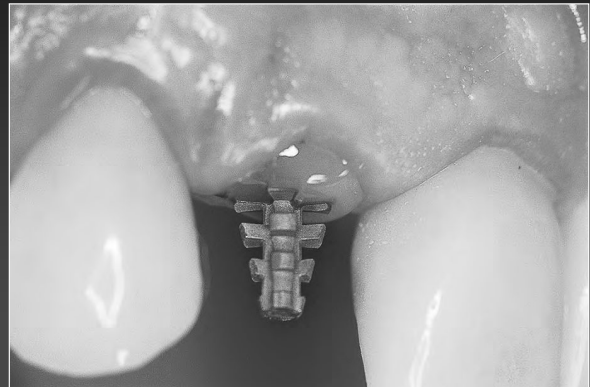
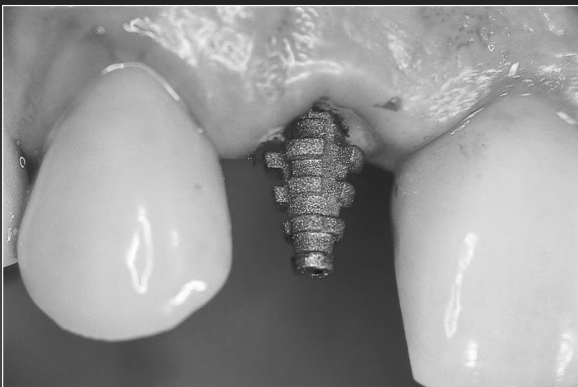● STIFTZAHN ABGEBROCHEN

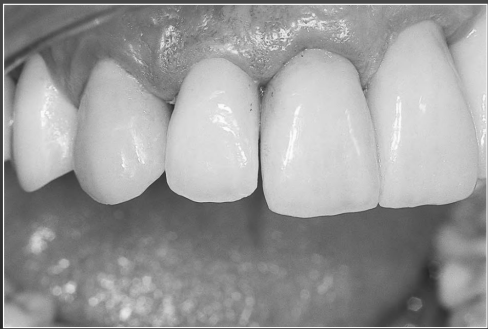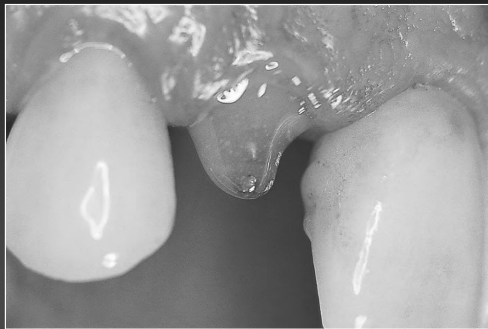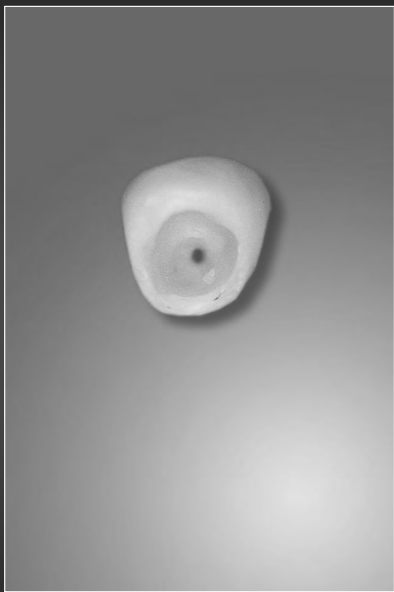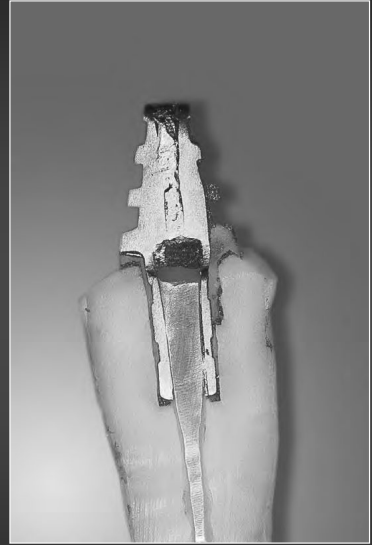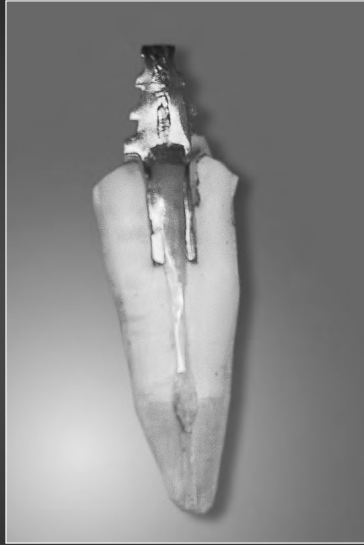






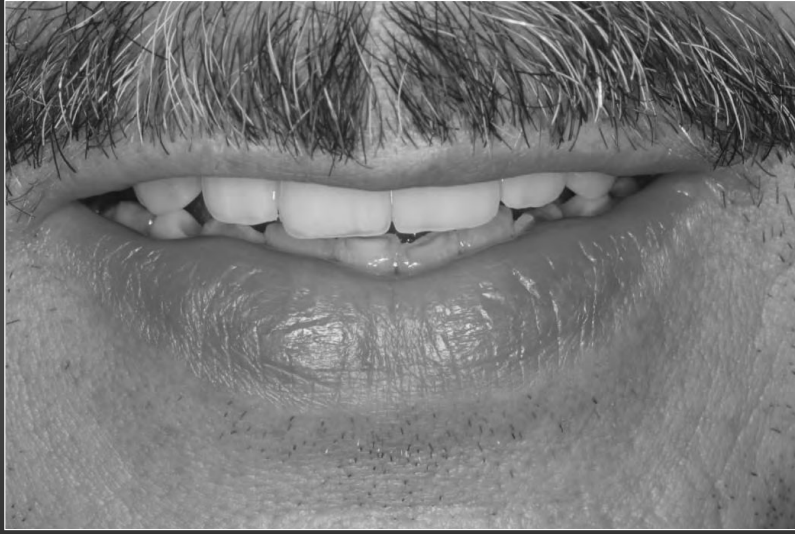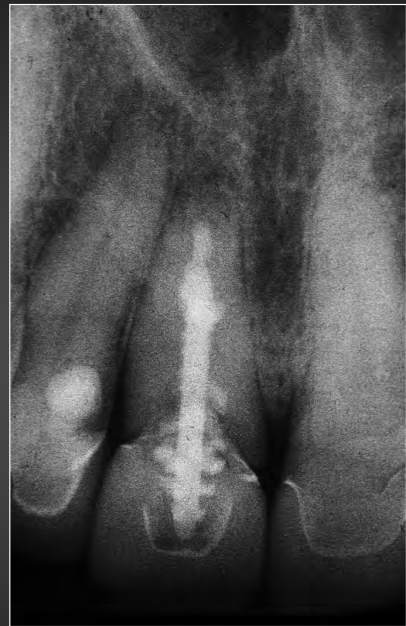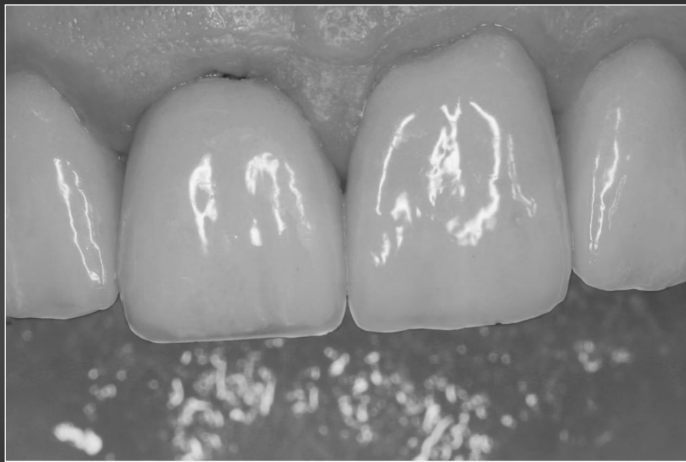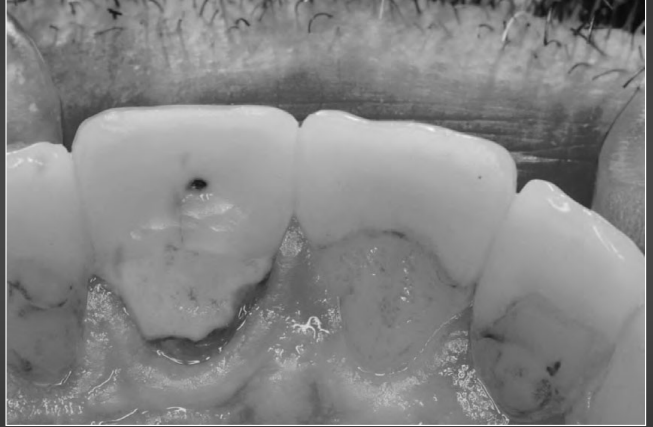







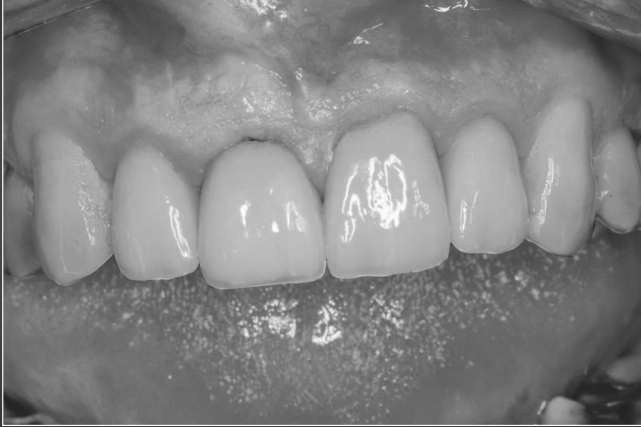


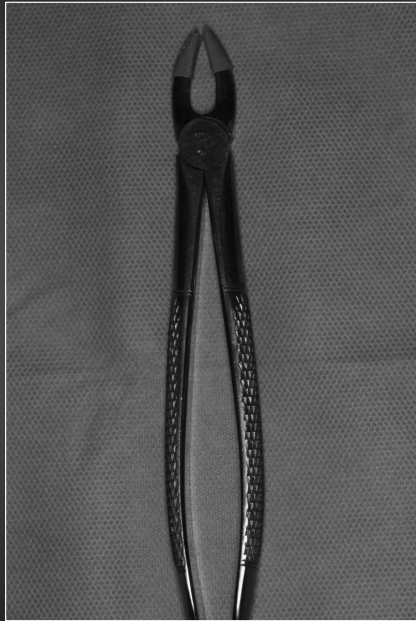
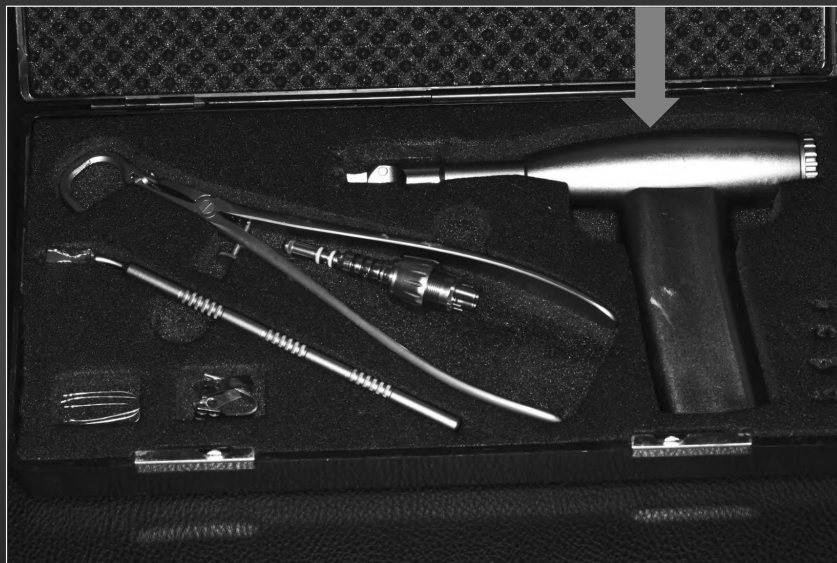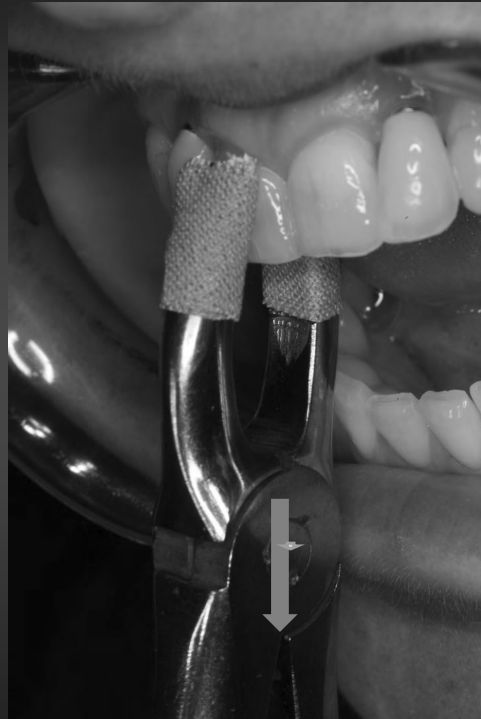● **SOFORTIMPLANTATION**



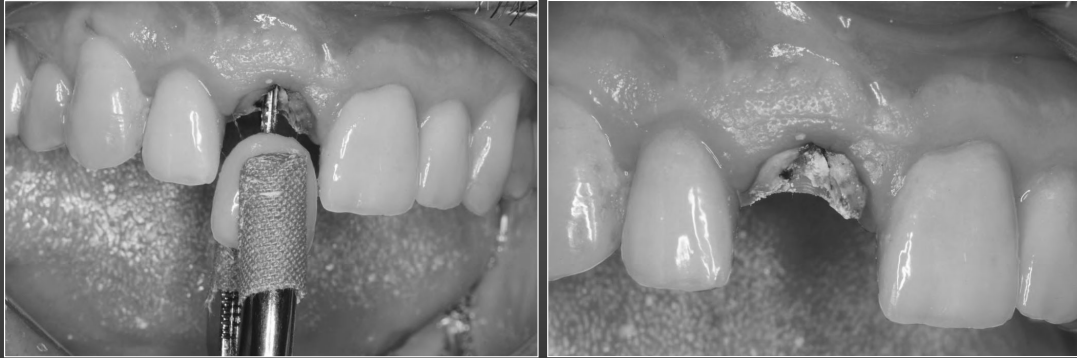


CORONAFLEX *KaVo*

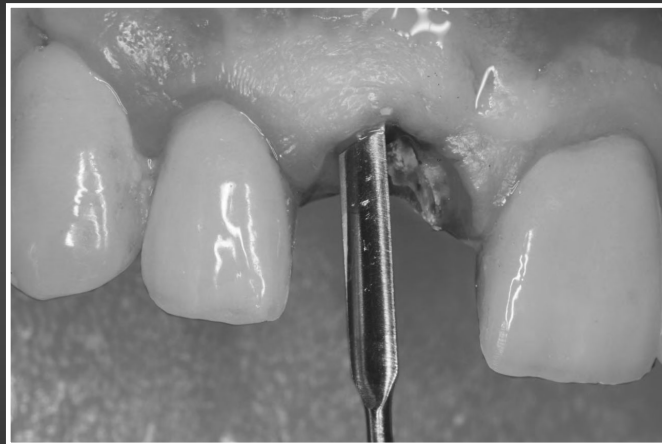
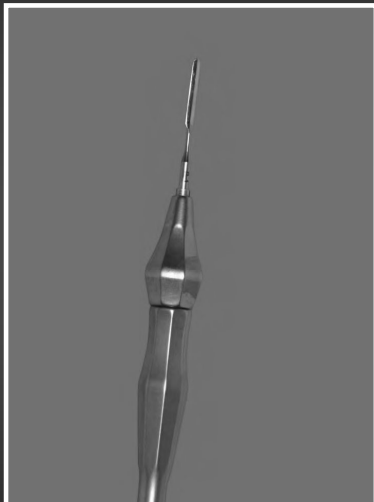




STIFTKRONENABNAHME

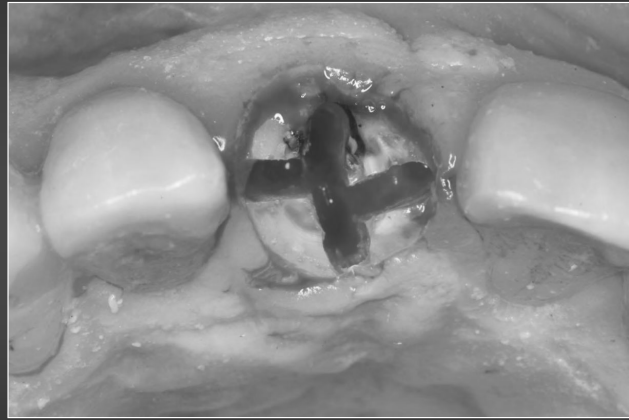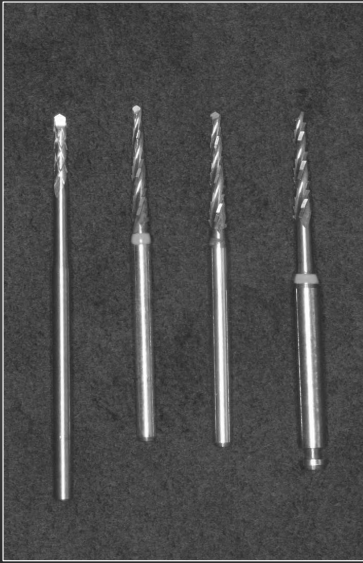


EXTRAKTION



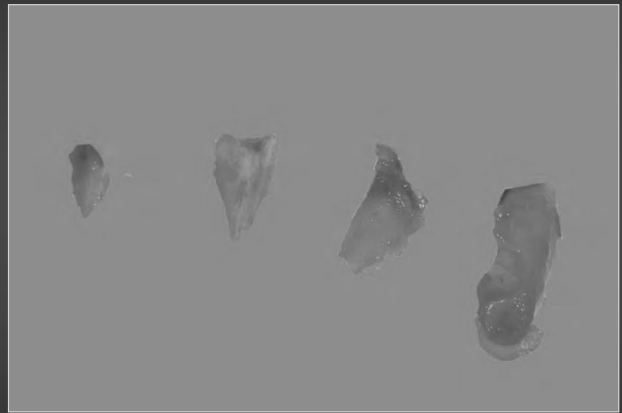
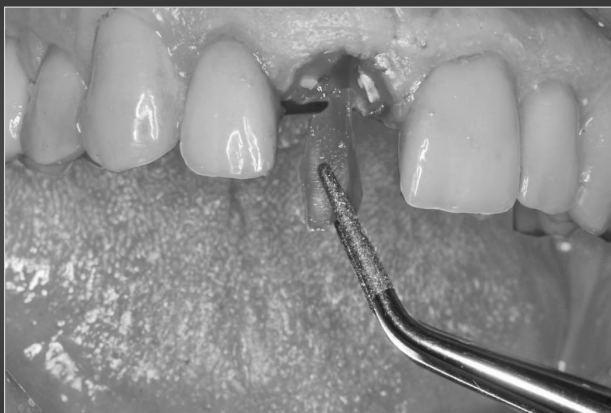Das Periotom nach Schulte

SEPARATION

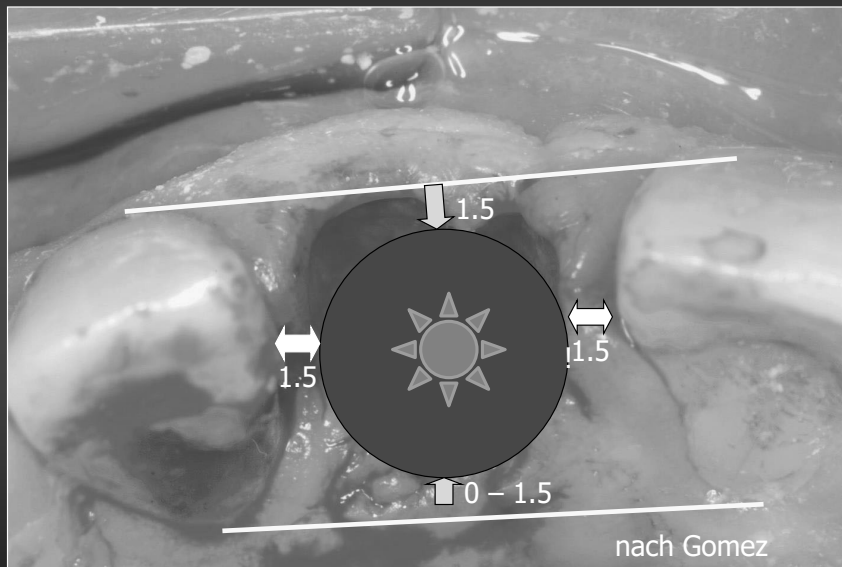


Der Separierfräsen

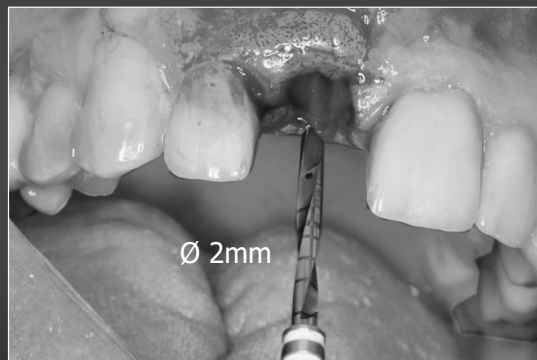
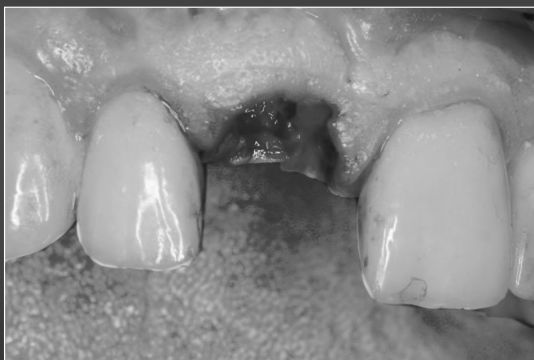EXTRAKTION



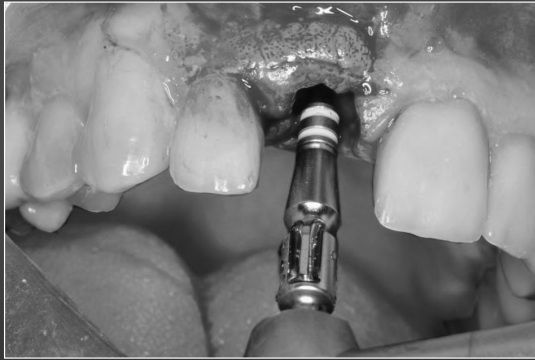ÄSTHETISCHES FENSTER



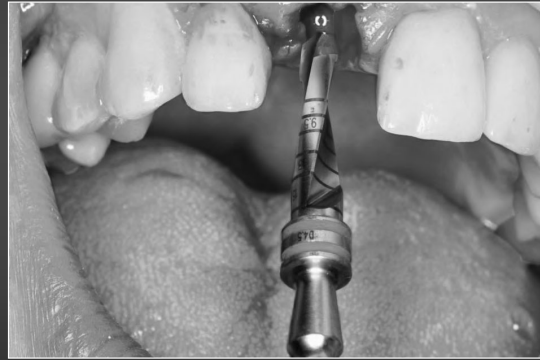INITIALE BOHRUNG



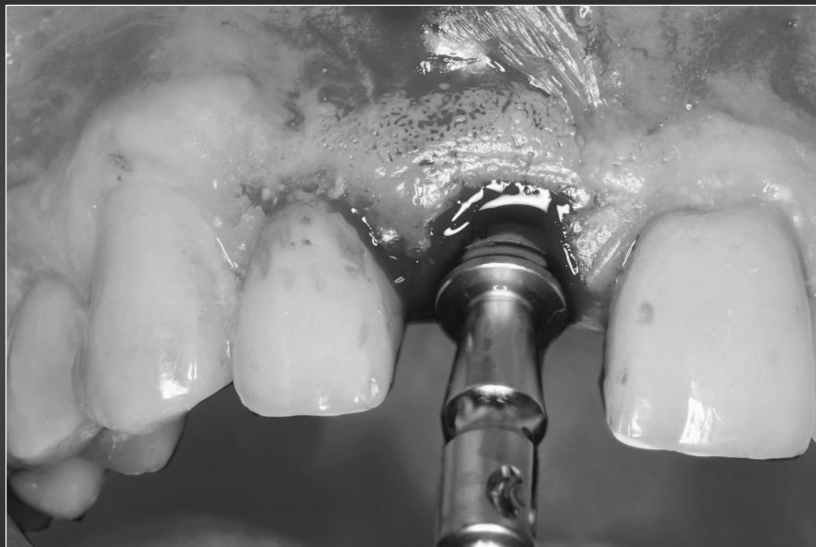IMPLANTATBETTAUFBEREITUNG

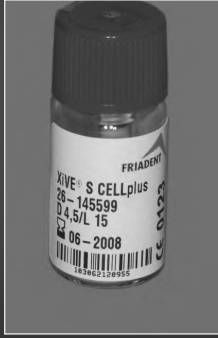

Ø 2mm

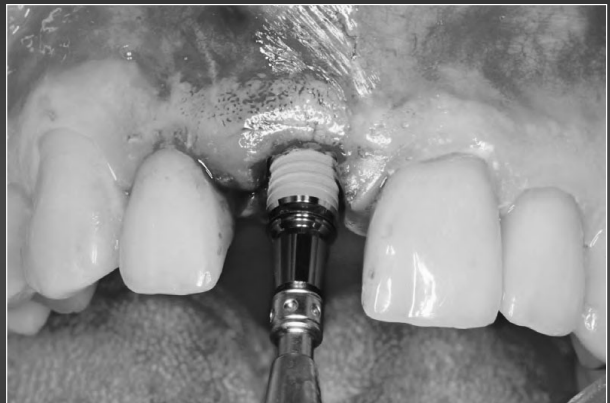
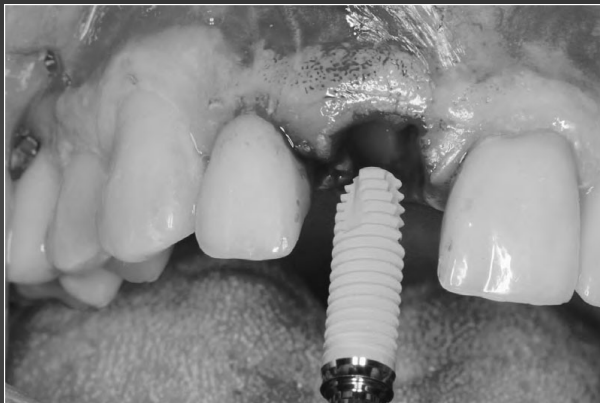
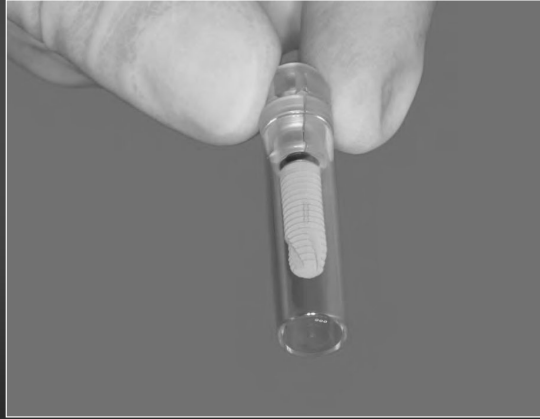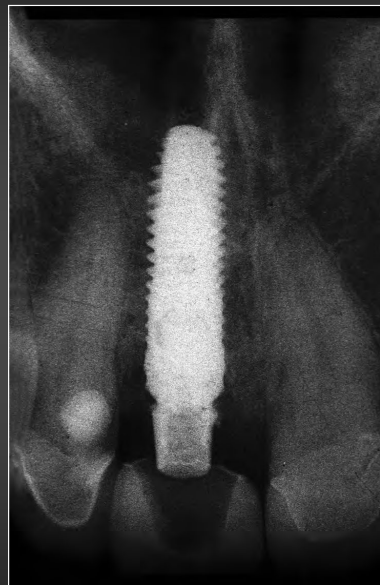
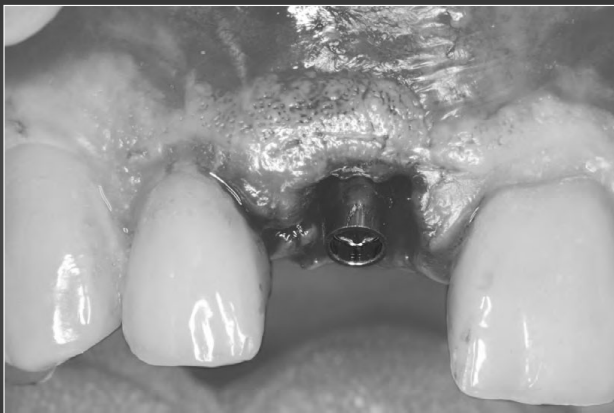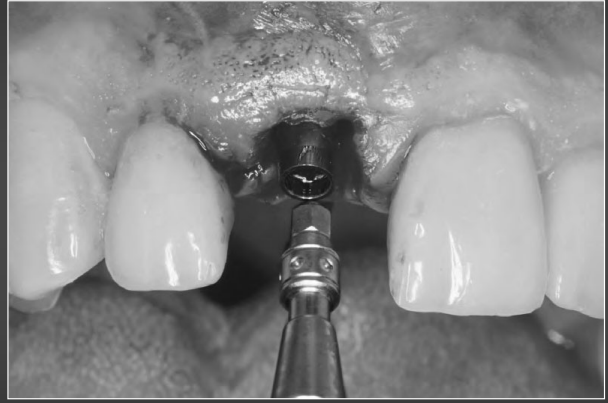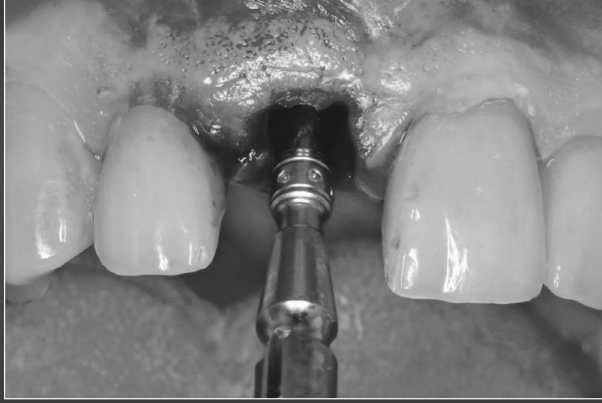Ø 4.5mm

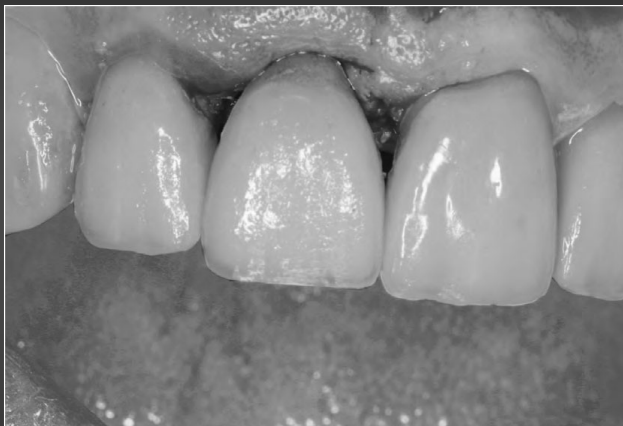
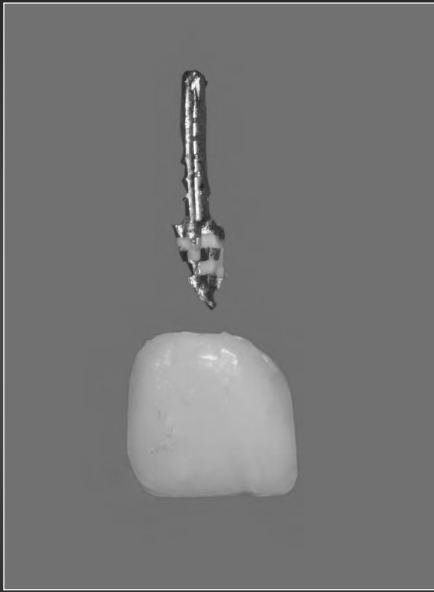


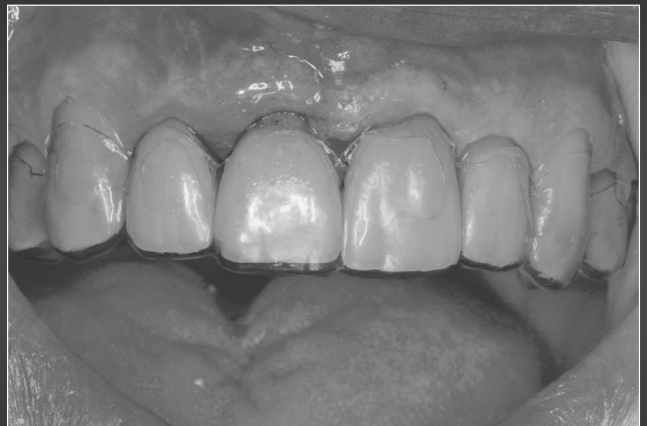XIVE Ø 4.5 L 15



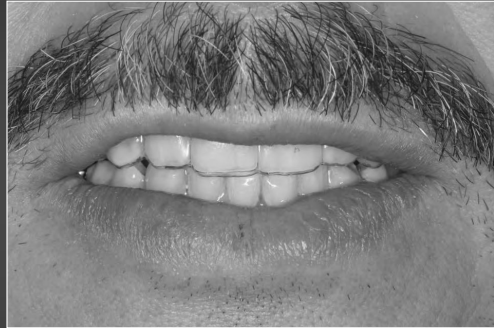
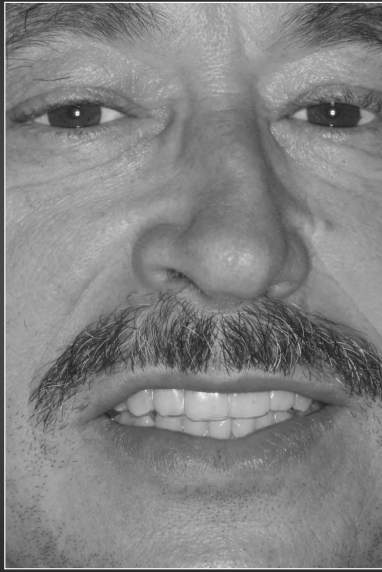



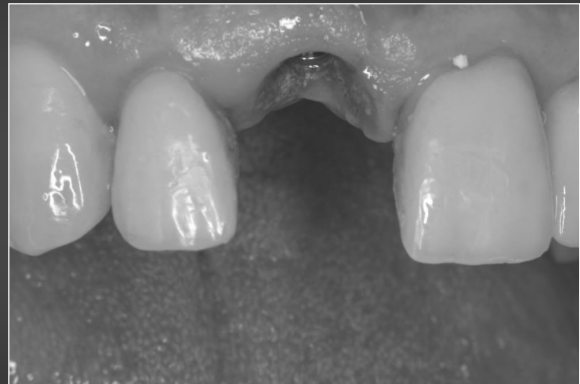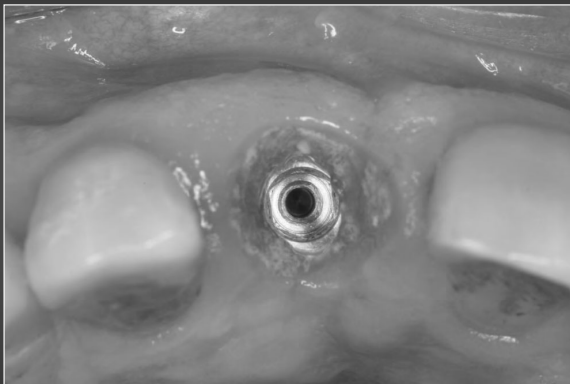
Die provisorische Krone



Die Schutzschiene



DEFINITIVE VERSORGUNG

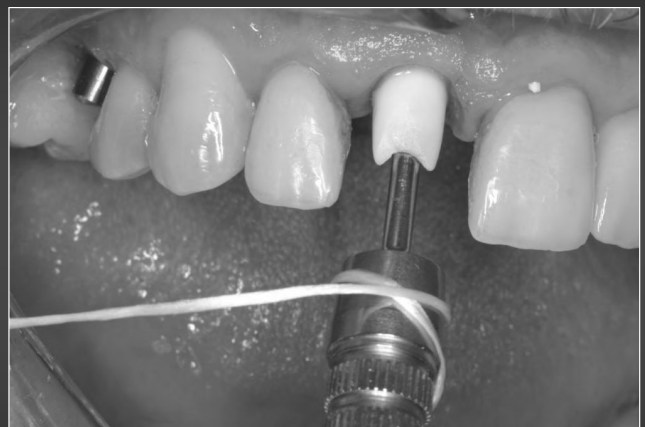

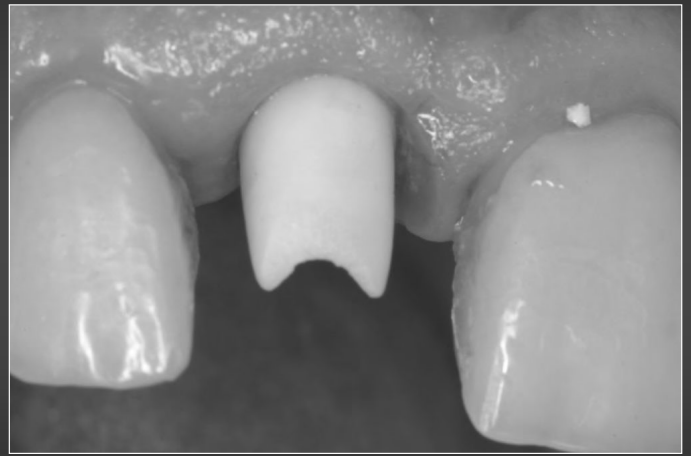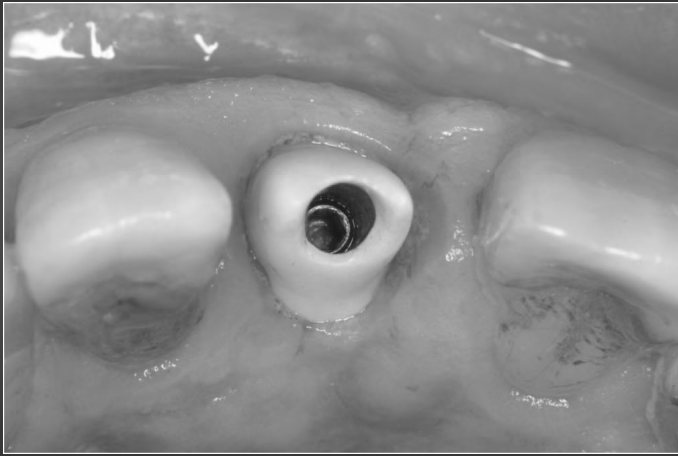
KERAMIKAUFBAUTEN



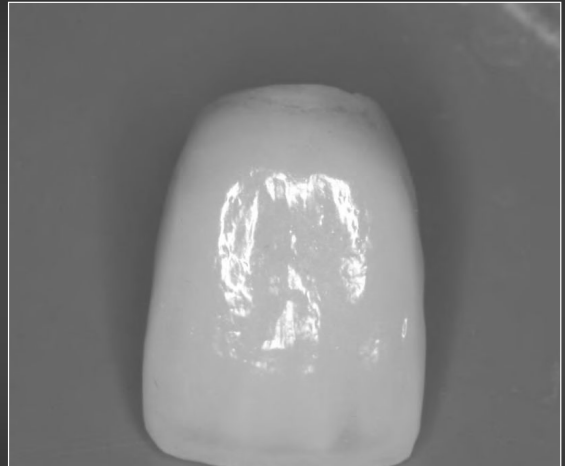
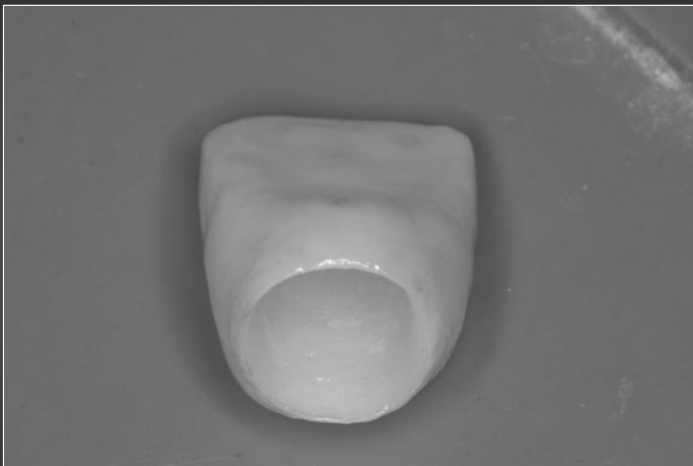
CERABASE AUFBAUTEN

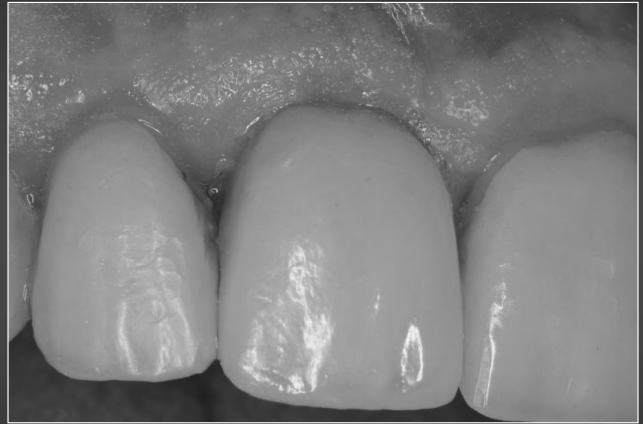
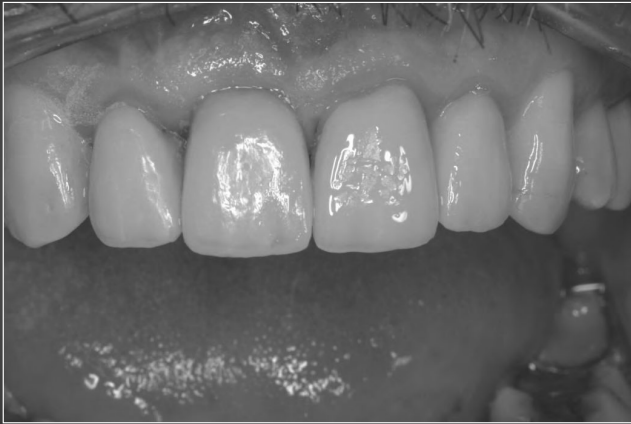FRIADENT



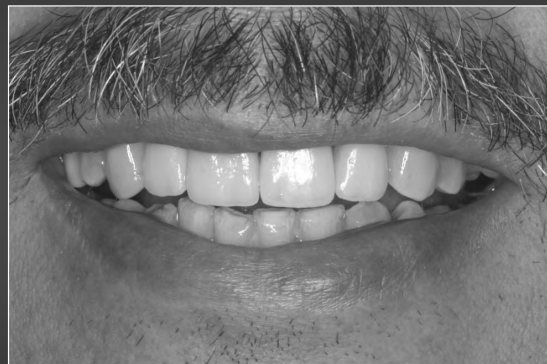

30 Ncm





DER PATIENT



STRAHLT.....



Dr. Wolfram Bücking
Ravensburgerstr. 11/1
D-88239 Wangen im Allgäu



w.buecking@t-online.de
www.dr-buecking.de

- Es geht weiter mit Modul 2 Prothetik Erste Hilfe Teil 2